

Infrequency of gross skin lesions among Panamanian forest mammals with cutaneous leishmaniasis

ARISTIDES HERRER and HOWARD A. CHRISTENSEN

*Gorgas Memorial Laboratory, Apartado 6991, Panamá 5,
República de Panamá*

(Received 20 January 1975)

SUMMARY

Natural leishmanial infections among feral mammals in the Republic of Panama were studied in relation to gross skin alterations. Three dermatotropic species of *Leishmania*, *L. braziliensis*, *L. mexicana* and *L. hertigi*, isolated from 230 sylvatic animals of 5 mammalian orders were involved. In 205 (89%) of the cases there were no gross skin alterations. Cryptic infections of all three leishmanial species among wild animals were confirmed by culture and hamster inoculation. This type of infection was always present in the sloths, *Choloepus hoffmanni* and *Bradypus infusatus*, infected with *L. braziliensis* and in the porcupine, *Coendou rothschildi*, infected with *L. hertigi*. Suggestive skin alterations were encountered in 10 (4%) of infected animals. Only 15 (7%) of infected animals exhibited typical leishmanial lesions. It was possible to correlate skin depigmentation with the course of leishmanial infection in one animal, a young kinkajou, *Potos flavus*.

INTRODUCTION

Panamanian forest mammals naturally infected with *L. braziliensis* without gross skin alterations were found for the first time in 1956. The infections were discovered by heartblood cultures from several spiny rats, *Proechimys semispinosus*, although the presence of the parasite in the skin was not demonstrated (Gorgas Memorial Laboratory, Annual Report for 1956). Ten years later *L. hertigi* was discovered in skin smears from a porcupine, *Coendou rothschildi*, without manifesting any gross skin lesions. The scarcity of the parasite in the porcupine skin led to the development of a technique in which cultures are made from skin snips of animals (Herrer, Thatcher & Johnson, 1966). The intensive use of this technique during the following nine years showed that the absence of gross skin alterations is a common phenomenon in Panama among feral animals naturally infected with three dermatotropic species of *Leishmania*.

This paper deals with the gross appearance of the skin observed in forest mammals found with natural leishmanial infections in Panama between April 1965 and September 1974, and emphasizes the frequency of infections which do not produce gross skin alterations.

Table 1. *Skin appearance in Panamanian forest mammals with natural cutaneous leishmaniasis*

(April 1965-September 1974)

Vertebrate host	Number examined	Found infected	Type of infection*			Species of <i>Leishmania</i> involved
			I	II	III	
<i>Choloepus hoffmanni</i> (Two-toed sloth)	498	93	93	—	—	<i>L. braziliensis</i>
<i>Bradypus infuscatus</i> (Three-toed sloth)	187	2	2	—	—	<i>L. braziliensis</i>
<i>Nasua nasua</i> (Coati)	8	1	1	—	—	<i>L. braziliensis</i>
<i>Coendou rothschildi</i> (Porcupine)	117	104	104	—	—	<i>L. hertigi</i>
<i>Agouti paca</i> (Paca)	8	1	1	—	—	<i>L. mexicana</i>
<i>Proechimys semispinosus</i> (Spiny rat)	789	8	4	4	—	<i>L. mexicana</i>
<i>Aotus trivirgatus</i> (Night monkey)	65	1	—	1	—	<i>L. braziliensis</i>
<i>Saguinus geoffroyi</i> (Marmoset)	91	1	—	1	—	<i>L. braziliensis</i>
<i>Bassaricyon gabbii</i> (Olingo)	9	1	—	1	—	<i>L. braziliensis</i>
<i>Potos flavus</i> (Kinkajou)	114	2	—	2	—	<i>L. braziliensis</i>
<i>Diplomys labilis</i> (Arboreal spiny rat)	41	1	—	1	—	Uncertain
<i>Marmosa robinsoni</i> (Brown murine opossum)	70	1	—	—	1	<i>L. mexicana</i>
<i>Oryzomys capito</i> (Rice rat)	111	14	—	—	14	<i>L. mexicana</i>
	2108	230	205	10	15	
		(100%)	(89%)	(4%)	(7%)	

* I, Cryptic infection; II, with suggestive skin lesions; III, with typical skin lesions

MATERIALS AND METHODS

Material. A total of 230 feral mammals naturally infected with dermatotropic species of *Leishmania* were studied. Thirteen forest mammalian host species belonging to the orders Edentata, Rodentia, Carnivora, Primates and Marsupialia were infected with *L. braziliensis*, *L. mexicana* or *L. hertigi*. The material studied was gathered during the course of a long-term investigation on reservoir hosts of cutaneous leishmaniasis in the Republic of Panama. Most of the ecological and epidemiological information concerning these studies has been published previously (Herrer, Telford & Christensen, 1971; Herrer, Christensen & Beumer, 1973).

Study methods. Animals studied were collected in the forest and brought to the laboratory in Panama city; most of them were trapped alive. Cultures from several bare areas of the skin, smears from skin lesions and blood cultures were made from these animals. Techniques used have been described in a previous publication (Herrer *et al.* 1973). Infected animals were examined repeatedly. Skin sections were made only from porcupines.

RESULTS

Cryptic infections. Infections in 2 species of sloths, *Choloepus hoffmanni* (Pl. 1A) and *Bradypus infuscatus*, with *L. braziliensis* as well as in the porcupine, *Coendou rothschildi* (Pl. 1B), with *L. hertigi* consistently failed to produce any macroscopically detectable skin alteration.

Table 2. Cultures made for *Leishmania* from depigmented areas of the skin from a young kinkajou, *Potos flavus*

	Time after arrival			
	10 days	1 month	3 months	5 months
Right ear	-	+	-	-
Left ear	+	+	-	-
Nose	+	+	+	-

Symbols used: +, positive; -, negative.

Suggestive skin alterations. Slight incrustations and/or depigmentations, generally on the inner aspect of the ear in animals such as the arboreal spiny rat, *Diplomys labilis* (Pl. 1C) and the olingo, *Bassaricyon gabbii* (Pl. 1D), have yielded dermatotropic species of *Leishmania* in culture. However, similar manifestations due to infestations of trombiculid mites and other sources of trauma complicate the diagnosis (Herrer *et al.* 1971).

Typical leishmanial skin lesions. Definite skin alterations were found in the rice rat, *Oryzomys capito*, infected with *L. mexicana*. These were destructive lesions on the tail which were frequently covered by scaly-like crusts (Pl. 1E). After healing, such lesions left a characteristic depigmented and rather depressed scar (Pl. 1F, arrow). A brown murine opossum, *Marmosa robinsoni*, also infected with *L. mexicana*, showed an ulcerated lesion at the base of the tail (Pl. 1G). Table 1 illustrates the number and proportion of each of these types of infections among Panamanian forest mammals.

It was possible to associate skin depigmentation with the course of a leishmanial infection in a very young kinkajou. This animal was captured in Trinidad Las Minas, central Panama, 28 September 1970. Ten days later it was carefully examined in the laboratory, and large depigmented areas of the skin were observed on the nose and both ears (Pl. 2A). Skin smears from both ears as well as the aspirate material cultured from the right ear were negative; however, cultures from the other ear and the nose were positive for *L. braziliensis*. Subsequent cultures from the same depigmented areas were made at 1, 3 and 5 months (Table 2). During this period of time the depigmentation regressed in all areas affected (Pl. 2B, C, D), in parallel with the disappearance of the parasite.

DISCUSSION

In 205 (89%) of 230 Panamanian forest mammals with natural leishmanial infections the skin did not show any gross alteration indicative of the infection (Table 1). Two species of sloths, *C. hoffmanni* and *B. infuscatus*, infected with *L. braziliensis*, together with the porcupine, *C. rothschildi*, infected with *L. hertigi*, accounted for 199 (97%) of the cryptic infections observed. The 6 (3%) remaining cases were represented by 5 rodents infected with *L. mexicana* and a single carnivore infected with *L. braziliensis*. These figures indicate that cryptic leishmanial infections are common among Panamanian forest mammals and are produced by all three dermatotropic species of *Leishmania* present in this country.

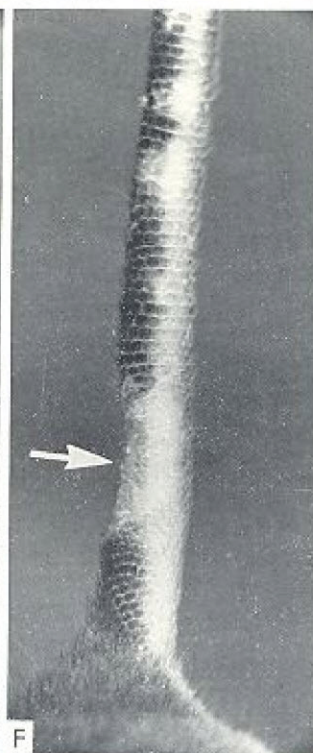
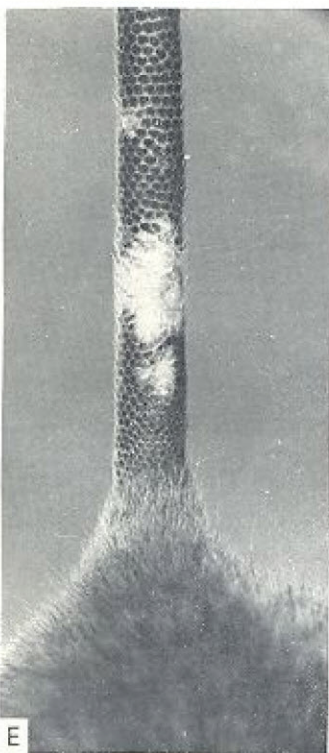
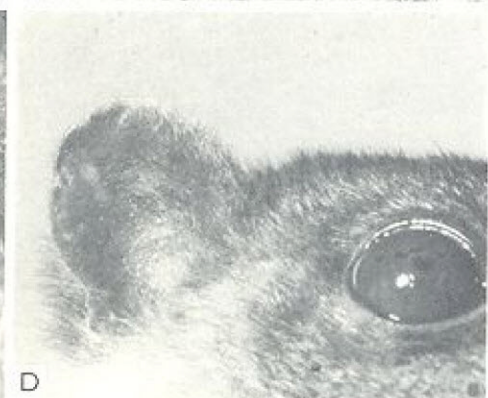The cryptic nature of leishmanial infections in the two-toed sloth is especially important from the public health point of view, since this edentate is the principal reservoir host of human leishmaniasis in central Panama (Herrer *et al.* 1973). Due to the complete absence of gross skin alterations in this animal infections have been overlooked in the past; the parasite was demonstrated only when the tissue-biopsy-culture technique was used. It is probable that the use of this technique in other areas of the New World would reveal similar cryptic infections in sloths.

The occult nature of *L. hertigi* infections in porcupines, the wide distribution of the parasite throughout the skin of its host and the persistence of the infections are remarkable. These characteristics, and the absence of marked tissue or cell reactions to the infection, indicate a well balanced host-parasite relationship of an ancient origin which has probably evolved from a parasitic association to a commensal one. It is difficult to assess the significance of the cryptic infection of the other six animals, 5 rodents infected with *L. mexicana* and a single carnivore infected with *L. braziliensis*.

Cutaneous leishmanial infections in animals with sound skin merit further investigations to assess their real significance and frequency in different areas. The possibility of leishmanial infection in forest mammals of the neotropics with the absence of ulcerated lesions was suggested more than a half century ago (Brumpt & Pedroso, 1913) and, according to our information, the first cryptic cases of cutaneous leishmaniasis in animals were demonstrated among dogs in the Peruvian highlands (Herrer, 1951). Recent publications by other workers reported asymptomatic infections by *L. mexicana* in the spiny rat, *P. guyanensis* in Brasil (Lainson & Shaw, 1974) and by *L. aethiopica* in 2 species of hyrax in Ethiopia (Ashford, Bray, Hutchinson & Bray, 1973). The latter report is of particular importance, since it shows that occult infections due to dermatotropic species of *Leishmania* are also found in the Old World.

In view of the frequency of cryptic leishmanial infections observed among feral mammals during the last few years, previous tenets concerning the nature of the vertebrate phase of the infections must be modified to provide a more comprehensive understanding of the host-parasite relationship. This, obviously, will necessitate a revision of some of our present concepts concerning the reservoir host of leishmaniasis as a whole.

Investigations reported in this article were partially supported by a research grant (AI-01251) from the NIAID, NIH, U.S. Public Health Service. We thank Mrs Ana Maria de Vásquez and Mr Leopoldo De León for their technical assistance.





A



B



C



D

REFERENCES

- ASHFORD, R. W., BRAY, M. A., HUTCHINSON, M. P. & BRAY, R. S. (1973). The epidemiology of cutaneous leishmaniasis in Ethiopia. *Transactions of the Royal Society of Tropical Medicine and Hygiene* **67**, 568-601.
- BRUMPT, E. & PEDROSO, A. (1913). Pesquisas epidemiologicas sobre a leishmaniose americana das florestas no Estado de Sao Paulo (Brasil). *Annaes Paulistas de Medicina e Cirurgia* **1**, 97-136.
- GORGAS MEMORIAL LABORATORY, ANNUAL REPORT FOR 1956. U.S. Govt Printing Office, 1957.
- HERRER, A. (1951). Estudios sobre leishmaniasis tegumentaria en el Perú. V. Leishmaniasis natural en perros procedentes de localidades utogenas. *Revista de Medicina Experimental (Lima)* **8**, 87-118.
- HERRER, A., THATCHER, V. E. & JOHNSON, C. M. (1966). Natural infections of *Leishmania* and trypanosomes demonstrated by skin culture. *Journal of Parasitology* **52**, 954-7.
- HERRER, A., TELFORD, S. R., JR & CHRISTENSEN, H. A. (1971). Enzootic cutaneous leishmaniasis in eastern Panama. I. Investigation of the infection among forest mammals. *Annals of Tropical Medicine and Parasitology* **65**, 349-58.
- HERRER, A., CHRISTENSEN, H. A. & BEUMER, R. J. (1973). Reservoir hosts of cutaneous leishmaniasis among Panamanian forest mammals. *American Journal of Tropical Medicine and Hygiene* **22**, 585-91.
- LAINSON, R. & SHAW, J. J. (1974). Las leishmanias y la leishmaniasis del Nuevo Mundo, con particular referencia al Brasil. *Boletin Oficina Sanitaria Panamericana* **76**, 93-114.

EXPLANATION OF PLATES

PLATE I

Skin appearance in forest mammals naturally infected with dermatotropic species of *Leishmania*.

- A. Two-toed sloth, *Choloepus hoffmanni*, infected with *L. braziliensis*. The parasite was consistently isolated in culture from sound skin mainly from the nose, jaw and ears.
- B. Tropical porcupine, *Coendou rothschildi*. This rodent showed a high infection rate due to *L. hertigi*. The parasite was found throughout the skin without any macroscopic skin alteration.
- C. Incrusted lesions at the border of both ears (arrows) in an arboreal spiny rat, *Diplomys labilis*. A dermatotropic species of *Leishmania*, not identified as yet, was isolated in culture from the right ear on the 6th and 30th days after its capture; simultaneous cultures from the other ear yielded negative results. The lesions from both ears almost disappeared during the time (1 month) the animal was maintained alive in the laboratory.
- D. Small, rounded and depigmented areas on the lower aspect of right ear in an olingo, *Bassaricyon gabbii*, from which *L. braziliensis* was cultured.
- E. Active lesion due to *L. mexicana* at the base of the tail of a rice rat, *Oryzomys capito*. Initially the lesion was prominent, whitish in colour, denuded of hair and covered by scaly-like crusts.
- F. Typical scar of leishmanial etiology on the tail of the rice rat. The scars are conspicuously depigmented, depressed (arrow) and usually located near the base of the tail.
- G. Ulcerated skin lesion at the base of the tail of a brown murine opossum, *Marmosa robinsoni*, from where *L. mexicana* was observed in skin smears. The parasite was isolated in culture twice during the period of 24 days the animal was maintained alive in the laboratory. The lesion was rounded in outline and 7 mm in diameter, and resembled human ulcerated lesions produced by *L. braziliensis* in Panama.

PLATE 2

Correlation between skin depigmentations and the course of a natural infection of *Leishmania braziliensis* in a young kinkajou, *Potos flavus*.

A. Ten days after capture. Large depigmented areas of the skin around the nose and the lower aspect of both ears. Cultures from aspirated material of the left ear and nose were positive, while those from the right ear were negative.

B. One month after capture. The depigmentation on the nose was considerably reduced. Positive cultures were obtained from the nose and both ears.

C. Three months after capture. Depigmentations of the nose and the left ear smaller than before; that of the right ear, unchanged. Cultures: positive from the nose; negative, from both ears.

D. Five months after capture. The depigmentation of the right ear had disappeared, and that of the left one was reduced to a small spot. Also the depigmentation of the dorsal aspect of the nose was smaller; however, the depigmentation on the lower border of the left nostril was larger. Negative cultures were obtained from the ears and the nose.